



2-Hydroxyglutaric aciduria as a cause for seizure-like episodes in a domestic shorthair cat

George J Nye , Alison C Major and Francois X Liebel

Journal of Feline Medicine and Surgery Open Reports
1–5

© The Author(s) 2019

Article reuse guidelines:

sagepub.com/journals-permissions

DOI: 10.1177/2055116919853898

journals.sagepub.com/home/jfmsopenreports

This paper was handled and processed by the European Editorial Office (ISFM) for publication in *JFMS Open Reports*



Abstract

Case summary A 14-month-old male castrated domestic shorthair cat, which 2 months prior to presentation underwent hindlimb amputation following a road traffic accident, presented for investigation of four suspected generalised tonic–clonic seizures. Neurological examination was unremarkable. Routine blood work (haematology, biochemistry, ammonia, preprandial bile acids) was unremarkable. MRI of the brain identified marked symmetrical T2-weighted hyperintensities of the cerebellum and brainstem, mainly affecting the grey matter. Urine amino acid and mucopolysaccharide levels were unremarkable. Urine organic acids on two separate samples, 35 days apart, identified highly increased excretion of 2-hydroxyglutaric acid, indicative of 2-hydroxyglutaric aciduria. The cat was started on anticonvulsant therapy with phenobarbitone, which, at the point of writing, has improved seizure control, although the cat has not achieved seizure freedom.

Relevance and novel information This case report describes the first reported case of a 2-hydroxyglutaric aciduria, an inherited neurometabolic disorder, as a cause for seizure-like episodes in a cat.

Keywords: 2-Hydroxyglutaric aciduria; cerebellar nuclei; magnetic resonance imaging

Accepted: 8 May 2019

Introduction

2-Hydroxyglutaric acidurias (2-HGA) are a group of inherited neurometabolic disorders, recognised in human and canine populations,^{1–3} occurring as a result of an inborn error of metabolism. Although, to our knowledge, there is no reported presentation in cats, the condition is well described in dogs with gait dysfunction, body and/or head tremors and seizure-like/dyskinetic episodes reported in Staffordshire Bull Terriers.³ There are two chiral forms: L-2-HGA and D-2-HGA, with a third, mixed form D-, L-2-HGA reported in human medicine.⁴ L-2-HGA has been described in Staffordshire Bull Terriers,^{2,3} a West Highland White Terrier⁵ and Yorkshire Terriers.⁶

Lysosomal storage diseases are widely recognised in the feline population.^{7–9} The clinical signs are often thought to be secondary to intracellular accumulation of by-products due an interrupted metabolic pathway. There is a vast array of clinical signs associated with these diseases,⁹ including behavioural change, ataxia, loss of learned behaviour, seizure activity, proprioceptive

deficits, tremors and dysmetria. Reports of inherited acidurias in cats causing neurological dysfunction are rare,^{10,11} In primary hyperoxaluria with L-glyceric aciduria, the renal tubules and axons within the dorsal root ganglia are primarily affected, causing renal failure and a peripheral neuropathy manifesting as weakness.¹⁰ There have been reports of acquired methylmalonic aciduria in cats secondary to cobalamin deficiency.^{12,13} In the case where cobalamin deficiency was suspected, the cat had signs consistent with an encephalopathy, including behavioural change, mental dullness and ataxia.¹²

School of Veterinary Science, Langford Small Animal Hospital, University of Bristol, Bristol, UK

Corresponding author:

George J Nye BVetMed, MRCVS, School of Veterinary Science, Langford Small Animal Hospital, University of Bristol, Bristol BS40 5DU, UK

Email: gn17257@my.bristol.ac.uk



Creative Commons Non Commercial CC BY-NC: This article is distributed under the terms of the Creative Commons

Attribution-NonCommercial 4.0 License (<http://www.creativecommons.org/licenses/by-nc/4.0/>) which permits non-commercial use, reproduction and distribution of the work without further permission provided the original work is attributed as specified on the SAGE and Open Access pages (<https://us.sagepub.com/en-us/nam/open-access-at-sage>).

The purpose of this report is to describe a case of 2-HGA in a cat and detail the diagnostic test results and response to therapy.

Case description

A 14-month-old male castrated domestic shorthair presented with a recent history of four self-limiting generalised tonic-clonic seizure-like episodes over a period of 1 month. The seizures were characterised by loss of consciousness, autonomic dysfunction (urination, defaecation, ptyalism) and tonic-clonic involuntary movement of all four limbs. These episodes lasted 2–3 mins and were accompanied by a postictal phase 30–120 mins in length, characterised by ataxia and a depressed mentation. In between the seizures, the cat was reported to act normally.

Two months prior to the episode history the cat was involved in a road traffic accident, causing irreparable left hindlimb trauma resulting in an amputation. General physical examination was otherwise unremarkable. No abnormalities were noted on neurological examination.

Based on the presence of generalised tonic-clonic seizures the cat was suspected to have a disease process affecting the forebrain.

Results of haematological examination, including smear evaluation, identified mild microcytosis (mean cell volume 41.2 fl; reference interval [RI] 41.3–52.6 fl), while white blood cell morphology was otherwise unremarkable. Complete serum biochemistry analysis was unremarkable. Preprandial bile acid was unremarkable while blood ammonia was mildly elevated (89.9 $\mu\text{mol/l}$ [RI 0–50 $\mu\text{mol/l}$]). Cerebrospinal fluid analysis, including total protein, total nucleated cell count and cytology, was unremarkable. Serum cobalamin level was elevated (1294 pmol/l [RI 231–617 pmol/l]).

An MRI study of the brain using a 1.5 T magnet (Philips Ingenia CX) was performed with the cat under general anaesthesia. The following sequences with a slice thickness of 2 mm were acquired: sagittal T2-weighted (T2W) turbo spin echo (TSE) and transverse T2W TSE, fluid-attenuated inversion recovery (FLAIR), T1-weighted (T1W) spin echo (SE), diffusion-weighted imaging with selection of three b-values (b 0, b 500, b 1000) and susceptibility-weighted imaging (VENBOLD). A three-dimensional (3D) T1W turbo field echo series with a slice thickness of 700 μm was also acquired. Following intravenous administration of gadolinium-based contrast medium (Prohance; Bracco Diagnostics) at a dose of 0.1 mmol/kg the transverse T1W SE and 3D TW1 TFS series were repeated.

There was marked T2W hyperintensity of the grey matter throughout the cerebellum and part of the mesencephalon (Figures 1 and 2), with no suppression on FLAIR and no associated contrast enhancement. This T2W hyperintensity was bilaterally symmetrical affecting the

caudal cerebellar peduncles, the deep cerebellar nuclei (dentate, interpositional and fastigial) (Figure 1) and the rostral and caudal colliculi (Figure 2).

Given the MRI findings and the cat's clinical presentation the presumptive diagnosis was an inherited neurometabolic disorder. Urine was submitted for mucopolysaccharide, amino acid and organic acid screening. A marked elevation of 2-hydroxyglutaric acid was identified. Repeat sampling 35 days later confirmed the same marked elevation of urinary 2-hydroxyglutaric acid.

Following MRI, the cat was started on 2 mg/kg oral solution of phenobarbitone q12h that was subsequently increased to 3 mg/kg q12h following a recrudescence

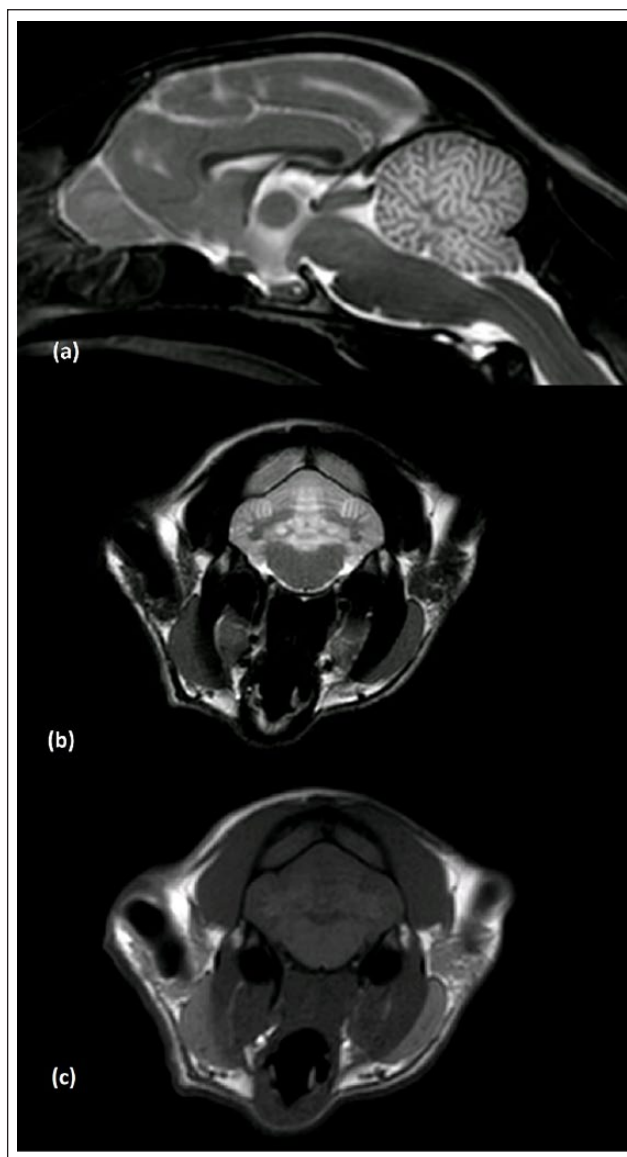


Figure 1 MRI images of the brain demonstrating the diffuse T2-weighted hyperintense lesions affecting the cerebellar cortex, deep cerebellar nuclei and mesencephalon: (a) sagittal; (b) transverse T2-weighted; and (c) T1-weighted images

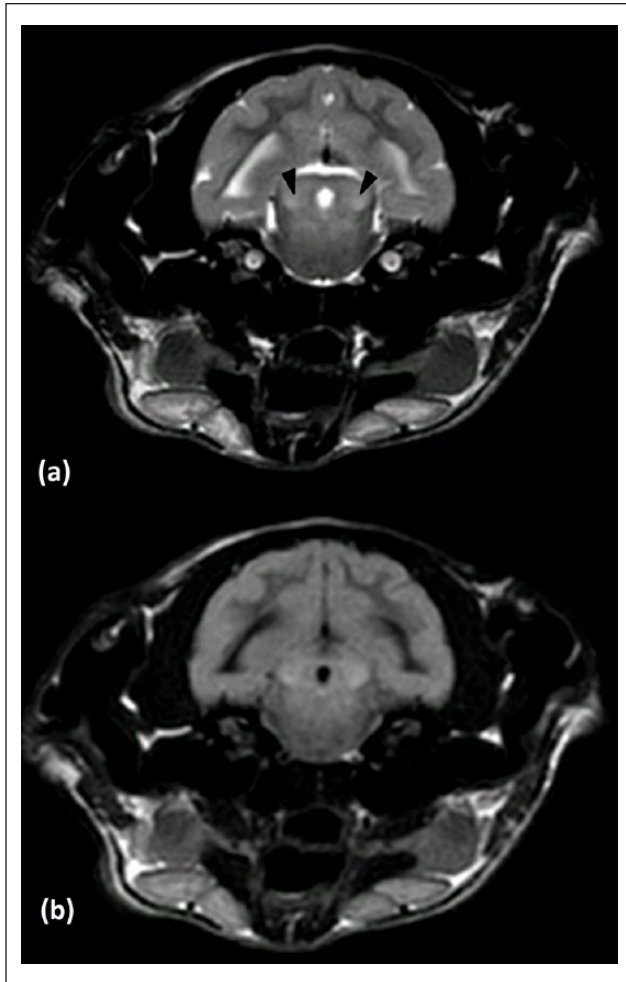


Figure 2 Transverse MRI images of the brain demonstrating the (a) T2-weighted and (b) fluid-attenuated inversion recovery hyperintensity of caudal colliculi (arrowheads)

of seizure activity. Following a telephone update at 12 months after diagnosis, the cat remains alive and has seizure episodes every 2–3 months.

Discussion

This is the first report, to our knowledge, that describes 2-HGA in a cat. Most cases identified in the veterinary literature are the L-2-HGA chiral form of the disease;^{2,3,5,6} however, the D-2-HGA form has been reported in an Irish Setter cross Labrador.¹⁴ The age of the cat (14 months) fits with the pattern seen in the Staffordshire Bull Terrier, with a mean age of onset of clinical signs reported at 12 months of age.³ Interestingly, the clinical signs manifesting in this case were generalised tonic-clonic seizures; however, the cerebral cortex appears to be unaffected on MRI. Seizures or seizure-like episodes are reported in both dogs^{2,3} and people,⁴ although there is some variation in these episodes, with dyskinesias appearing to be more common in dogs. No cellular

inclusion or lymphocyte changes were seen on blood smear examination. For example, vacuolation of some lymphocytes has been reported in mucopolysaccharidosis in the Siamese,⁹ but such changes are not present in some storage diseases. While the preprandial ammonia was mildly elevated, the level of elevation was considered insignificant. Based on this, in combination with normal resting serum bile acids, we considered hepatic encephalopathy very unlikely,¹⁵ and further investigation for hepatic dysfunction was not carried out.

L-2-HGA is well recognised in dogs, with characteristic MRI changes reported,^{2,5} including T2W hyperintensity of the thalamus, hypothalamus, dentate nucleus, basal ganglia, dorsal brainstem, cerebral cortex, cerebellar nuclei and cerebellar cortex. In people, the lesions are primarily seen in the frontal and subcortical white matter, although the dentate nuclei are also commonly affected.¹⁶ The changes seen in this cat affected mainly the cerebellar nuclei, cerebellar cortex and colliculi. The cerebral grey matter was spared, while it is typically markedly affected in dogs.² This leads to speculation as to whether this reflects the level of severity of the disease in this cat or indicates differences in the regions of metabolically susceptible neuronal tissue seen in cats vs dogs. Assessing severity of disease relating to imaging findings appears to be inconclusive in people.^{17,18} However, the chronicity of the disease can be indicated by MRI changes in people,¹⁶ with dentate nucleus and basal ganglia changes appearing early. Interestingly, L-2-HGA appears to affect the grey matter in dogs² but the white matter in people.¹⁶ There is no explanation for this difference, despite both people and dogs expressing the same genetic mutation. Based on the spectrum of MRI findings in this case, it is a reasonable hypothesis that this cat's MRI changes are likened to canine L-2-HGA.

The course of this disease seems relatively slowly progressive/static in nature, owing to the fact the cat is still alive 12 months after diagnosis, with episodes occurring every 2–3 months, with the same slow progression reported in Staffordshire Bull Terriers.³ The response to phenobarbitone in this cat would represent a complete treatment success based on the International Veterinary Epilepsy Task Force guidelines.¹⁹ There was a greater than three-fold increase in the post-treatment interictal period (60 days) vs the longest pretreatment interictal period (9 days). Other treatments used in people include flavin adenine dinucleotide, riboflavin and L-carnitine, with reports of decreased urinary L-2-hydroxyglutaric acid^{20,21} and improvement in motor and cognitive function resulting. In dogs there are reports of the use of L-carnitine³ or riboflavin and phenobarbitone²² with possible clinical improvement. In one previous report, a mild methylmalonic aciduria was identified in a dog alongside a diagnosis of L-2-HGA.² However, the authors did

not provide any explanation for such findings and, to our knowledge, there is no identified link between the two acidurias or between cobalamin deficiency and L-2-HGA.

Further areas for research would include genome sequencing of this cat to try and identify a causative mutation, like the variety of mutations of L-2-hydroxyglutarate dehydrogenase as seen in Stafford Bull Terriers and Yorkshire Terriers.^{23,24} It is possible this case is part of a familial genetic change or a one-off genetic anomaly. Unfortunately, the cat had no known siblings and therefore further familial information was not available. Repeat MRI would be beneficial to document a progression in the disease over time, as has been identified in people, with atrophy of the cerebral white matter and cerebellar hemispheres.¹⁶ A post-mortem examination would be beneficial for identifying histological changes; however, the success of the cat's response to anticonvulsant medication means that currently this is not a possibility. Prior to MRI, the presumptive diagnosis in this cat was idiopathic epilepsy. It is possible that feline 2-HGA is underdiagnosed given its slowly progressive nature and apparent response to treatment, as demonstrated in human and canine populations.³ It may masquerade as idiopathic epilepsy based on Tier 1 level of confidence in a non-referral population.²⁵

Limitations include the fact that this cat had a prior trauma. It is possible the seizure-like episodes are secondary to post-traumatic epilepsy. One previous study looking at the 2 year follow up of 52 cats following head trauma did not identify any post-traumatic seizures, although this may be an underestimation.²⁶ The reported prevalence in the canine population is 6–10%, secondary to traumatic brain injury;^{27,28} however, the MRI changes within the cerebellum and brainstem identified in this case are strongly suggestive of a metabolic brain disorder.

Conclusions

Although rare, 2-HGA should be considered as a differential in cats demonstrating seizures or seizure-like episodes.

Acknowledgements The authors thank Dr Adrian Sewell and Dr Martina Dick (Biocontrol – Labor für veterinärmedizinische Untersuchungen) for discussing results of the metabolic screening.

Conflict of interest The authors declared no potential conflicts of interest with respect to the research, authorship, and/or publication of this article.

Funding The authors received no financial support for the research, authorship, and/or publication of this article.

Ethical approval This work involved the use of client-owned animal(s) only and followed internationally recognised

high standards ('best practice') of individual veterinary clinical patient care. Ethical approval from a committee was not therefore needed.

Informed consent Informed Consent (either verbal or written) was obtained from the owner or legal guardian of all animal(s) described in this work for the procedure(s) undertaken. For any animals or humans individually identifiable within this publication, Informed Consent for their use in the publication (verbal or written) was obtained from the people involved.

ORCID ID George J Nye  <https://orcid.org/0000-0003-2029-2883>

References

- Duran M, Kamerling J, Bakker H, et al. **L-2-Hydroxyglutaric aciduria: an inborn error of metabolism?** *J Inherit Metab Dis* 1980; 3: 109–112.
- Abramson CJ, Platt SR, Jakobs C, et al. **L-2-hydroxyglutaric aciduria in Staffordshire bull terriers.** *J Vet Intern Med* 2003; 17: 551–556.
- Shea A, De Risio L, Carruthers H, et al. **Clinical features and disease progression of L-2-hydroxyglutaric aciduria in 27 Staffordshire bull terriers.** *Vet Rec* 2016; 179: 545–545.
- Kranendijk M, Struys EA, Salomons GS, et al. **Progress in understanding 2-hydroxyglutaric acidurias.** *J Inherit Metab Dis* 2012; 35: 571–587.
- Garosi L, Penderis J, McConnell J, et al. **L-2-hydroxyglutaric aciduria in a West Highland white terrier.** *Vet Rec* 2005; 156: 145–147.
- Sanchez-Masian DF, Artuch R, Mascort J, et al. **L-2-hydroxyglutaric aciduria in two female Yorkshire terriers.** *J Am Anim Hosp* 2012; 48: 366–371.
- Vandeveldel M, Fankhauser R, Bichsel P, et al. **Hereditary neurovisceral mannosidosis associated with α -mannosidase deficiency in a family of Persian cats.** *Acta Neuropathol* 1982; 58: 64–68.
- Baker HJ, Lindsey JR, McKhann GM, et al. **Neuronal GM1 gangliosidosis in a Siamese cat with β -galactosidase deficiency.** *Science* 1971; 174: 838–839.
- Skelly BJ and Franklin RJ. **Recognition and diagnosis of lysosomal storage diseases in the cat and dog.** *J Vet Intern Med* 2002; 16: 133–141.
- McKerrell R, Blakemore W, Heath M, et al. **Primary hyperoxaluria (L-glyceric aciduria) in the cat: a newly recognised inherited disease.** *Vet Rec* 1989; 125: 31–34.
- De Lorenzi D, Bernardini M, Pumarola MJJofm, et al. **Primary hyperoxaluria (L-glyceric aciduria) in a cat.** *J Feline Med Surg* 2005; 7: 357–361.
- Kelmer E, Shelton GD, Williams DA, et al. **Organic acidemia in a young cat associated with cobalamin deficiency.** *Journal of Veterinary Emergency Critical Care* 2007; 17: 299–304.
- Vaden S, Wood P, Ledley F, et al. **Cobalamin deficiency associated with methylmalonic acidemia in a cat.** *J Am Vet Med Assoc* 1992; 200: 1101–1103.
- Nyhan WL, Shelton GD, Jakobs C, et al. **D-2-hydroxyglutaric aciduria.** *J Child Neurol* 1995; 10: 137–142.
- Ruland K, Fischer A and Hartmann KJVCP. **Sensitivity and specificity of fasting ammonia and serum bile acids**

- in the diagnosis of portosystemic shunts in dogs and cats. *Vet Clin Pathol* 2010; 39: 57–64.
- 16 Steenweg ME, Salomons GS, Yapici Z, et al. **L-2-hydroxyglutaric aciduria: pattern of MR imaging abnormalities in 56 patients.** *Radiology* 2009; 251: 856–865.
 - 17 Barbot C, Fineza I, Diogo L, et al. **L-2-Hydroxyglutaric aciduria: clinical, biochemical and magnetic resonance imaging in six Portuguese pediatric patients.** *Brain Dev* 1997; 19: 268–273.
 - 18 Steenweg ME, Vanderver A, Blaser S, et al. **Magnetic resonance imaging pattern recognition in hypomyelinating disorders.** *Brain* 2010; 133: 2971–2982.
 - 19 Potschka H, Fischer A, Löscher W, et al. **International veterinary epilepsy task force consensus proposal: outcome of therapeutic interventions in canine and feline epilepsy.** *BMC Vet Res* 2015; 11: 177. DOI: 10.1186/s12917-015-0465-y.
 - 20 Samuraki M, Komai K, Hasegawa Y, et al. **A successfully treated adult patient with L-2-hydroxyglutaric aciduria.** *Neurology* 2008; 70: 1051–1052.
 - 21 Yilmaz K. **Riboflavin treatment in a case with l-2-hydroxyglutaric aciduria.** *Eur J Paediatr Neurol* 2009; 13: 57–60.
 - 22 Bóhm M, Henderson H, van der Zwan H, et al. **L-2 hydroxyglutaric aciduria in a South African Staffordshire Bull Terrier.** *J S Afr Vet Assoc* 2014; 85: 1–5.
 - 23 Penderis J, Calvin J, Abramson C, et al. **L-2-hydroxyglutaric aciduria: characterisation of the molecular defect in a spontaneous canine model.** *J Med Genet* 2007; 44: 334–340.
 - 24 Farias FH, Zeng R, Johnson GS, et al. **A L2HGDH initiator methionine codon mutation in a Yorkshire terrier with L-2-hydroxyglutaric aciduria.** *BMC Vet Res* 2012; 8: 124. DOI: 10.1186/1746-6148-8-124.
 - 25 De Risio L, Bhatti S, Muñana K, et al. **International veterinary epilepsy task force consensus proposal: diagnostic approach to epilepsy in dogs.** *BMC Vet Res* 2015; 11: 148. DOI: 10.1186/s12917-015-0462-1.
 - 26 Grohmann KS, Schmidt MJ, Moritz A, et al. **Prevalence of seizures in cats after head trauma.** *J Am Vet Med Assoc* 2012; 241: 1467–1470.
 - 27 Beltran E, Platt S, McConnell J, et al. **Prognostic value of early magnetic resonance imaging in dogs after traumatic brain injury: 50 cases.** *J Vet Intern Med* 2014; 28: 1256–1262.
 - 28 Steinmetz S, Tipold A and Löscher WJE. **Epilepsy after head injury in dogs: a natural model of posttraumatic epilepsy.** *Epilepsia* 2013; 54: 580–588.